

Excavations at Carmarthen Greyfriars 1983-1997

Analysis of Skeletal Remains



VOLUME I: Summary of Findings & Photographs

**Dr. J. L. Wilkinson,
formerly of the Anatomy Dept., University College, Cardiff**

TEXT EDITED BY TERRY JAMES *for* CAMBRIA ARCHAEOLOGY 2001

CONTENTS

VOLUME I SUMMARY OF FINDINGS

Hints on using this document **3**

Editorial Note **4**

Summary of Findings from the Cloisters and Chapter House (1984-1997) **5**

Summary of Findings from the Church (1988 & 1990) **13**

Summary Table (1988/1990 Seasons) **22**

Summary of 1997 Findings from the Choir **30**

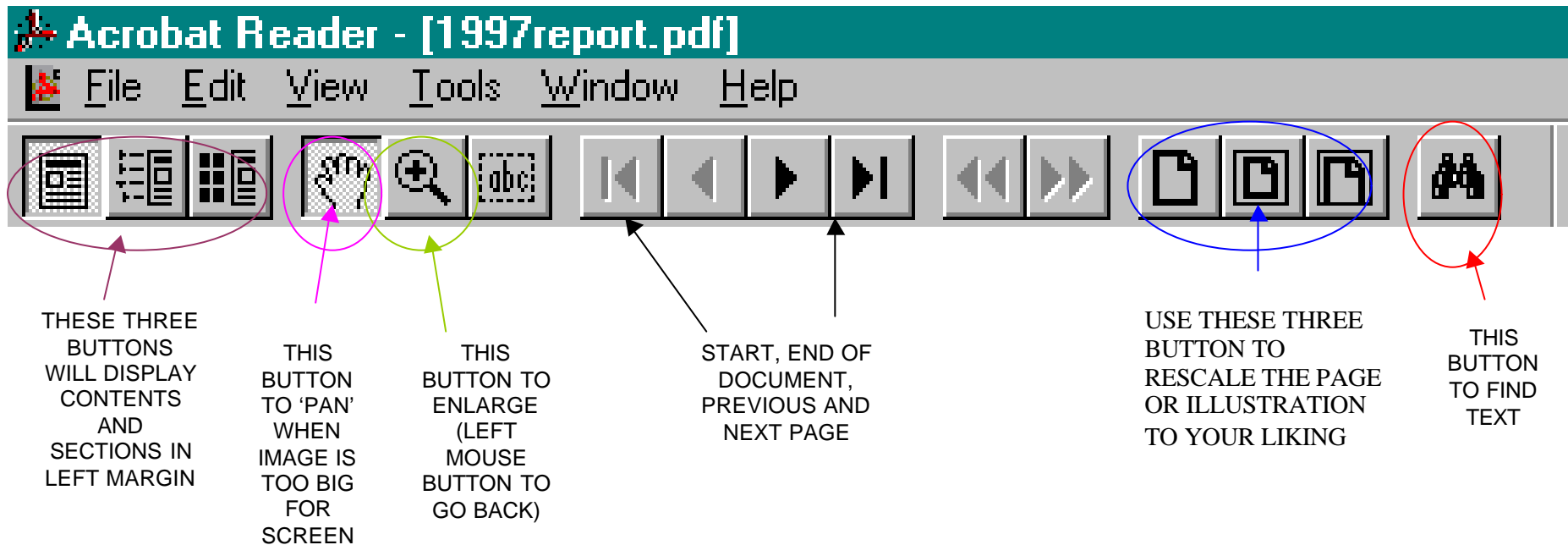
Photographs 36

VOLUME II DETAILED DESCRIPTIONS

Other reports in this series, published herewith in electronic format, are: **small finds; pottery** and **floor tiles** as well as the **1997** excavation report. The main structural report is published in *Medieval Archaeology*, Vol. xli 1997 pp. 100-194. The electronic publications can be read using Adobe® Acrobat.™ This can be freely download and used from <http://www.adobe.com/products/acrobat/readstep2.html>.

Hints on using this document:

Take a moment to learn how Acrobat works. Time spent now will help you harness the power and ease of moving around this electronic document. Text Marked like **this is a 'hot link'** (see the cursor changes to a POINTING HAND when you hover over red words). Click on any red words and letters: these will take you to the appropriate cross reference or illustration (**then use the right mouse button to return to original page**)



Note you can rescale a page and move to another page number by clicking on the relevant part of the lower left of the screen.

Editorial Note

The following bone reports were compiled by Dr Wilkinson at particular periods of the Greyfriars excavations. Given the rolling nature of redevelopment of the site it was never clear when the excavations would terminate. His reports were designed to stand on their own. The task of text editor has been to try to present a cohesive report, but neither time nor finance allows a complete restructuring. The individual synopses have been extracted and presented first (Volume I). Detailed descriptions are in Volume II. The method of analysing the bones was undertaken according to a skeleton's completeness. Complete skeletons, (or assemblages of individuals clearly identified on site), were examined first. Mixed assemblages of bone from common contexts followed after these. Because of this the descriptions do not follow a Context Number sequence, although within the working process described here numbers like, complete skeletons, tend to be sequential. After study the bones were interred in the graveyard of St. Mary's RC Church, Carmarthen, and Dr Wilkinson's typescript was deposited with the rest of the archive and finds in Carmarthen County Museum. Please note that Context Numbers for the 1997 report start afresh at No.1.

Conventions used for Dentition (Volume II)

The following notation has been adopted throughout this publication

<i>Usual convention</i>	<i>Meaning</i>	<i>Adopted Convention</i>	<i>Example</i>
χ	loss a.m.	double strikethrough	8
or /	loss p.m.	single strikethrough	8
υ	unerupted	inferior/subscript figure	8
ο	erupting	superior/superscript fig. underlined	<u>8</u>

ul=upper left (for MS.]) ll=lower left (for MS.])
ur=upper right (for MS. [) lr=lower right (for MS. [)

1984 to 1987 Excavations

SUMMARY OF FINDINGS FROM THE CLOISTERS AND CHAPTER HOUSE

There were 29 graves, of which 24 contained only one body. In 5 there were remains of another individual; four of these consisted of one or two bones only and were probably an accidental inclusion from an adjacent burial, either during inhumation or exhumation. Thus 34 individuals were represented in graves.

Apart from the grave burials there were 6 localized aggregations with a regional body representation adequate enough to indicate the burial of one individual in 4 sites and two individual admixed in each of 2 sites, i.e. eight burials. Altogether 42 people have been identified so far.

There were 17 other contexts in which small amounts of bone were found, most commonly from hand (4), foot (6) or skull(6). Two fragments were unidentified. These remains are regarded as either having been derived from a grave such as those already mentioned, or alternatively they may be the scattered remains from other disturbed graves.

In one location (context 871) there were the partial remains of an adult and an adolescent and in addition there was the very singular discovery of five left great toe metatarsal bones from adults. It is difficult to explain this. Obviously it is not the accidental residuum of five burials. It is most unlikely to have resulted from amputation or any other surgical intervention; the find is too selective and no operative procedure requires the individual removal of this bone. Occasionally, for example in some Anglo-Saxon cemeteries, the feet are buried separately presumably as a penal act or for reasons of superstition (see Wilkinson 1980).

It may be noted that here also, in context 722 there were the partial remains of a pair of feet, probably the result of grave disturbance. Occasionally, particularly in Roman or Roman-British remains, there are aggregations of identical animal bones,

particularly the astragali of sheep; these were used as counters, but there is no record of human bones being used as items of utility in Western societies. It may be some most unusual form of token burial or the result of some curious whim or custom.

Individual ages

It was possible to determine the ages of 34 individuals; these included 28 from graves and 6 not in graves. The ageing of adults was largely dependent upon the degree of dental attrition. Evidence of advancing age was supported by the presence of degenerative disease of joint surfaces, loss of teeth and changes in the he mandible. the degree of fusion of cranial sutures is not generally a reliable guide to the ageing process.

In immature skeletons there was a lack of fusion of long bone epiphyses, the bones also being of small size; the permanent dentition was incomplete and occasionally there was a persistence of deciduous teeth into adolescence. At intermediate ages between adolescence and adult life the fusion, or otherwise of the spheno-occipital synchondrosis, the development and fusion of the late accessory epiphyses of iliac crest, ischial tuberosity and vertebral bodies, the degree of fusion of sacrum or body of the sternum were of assistance in determining age.

The age range of 34 individuals was a follows:

-	-	-	-	-	-	+4
1	2	2	3	3	4	5
5	0	5	0	5	0	
4	7	4	1	2	8	8

It is surprising that 11 individuals (32%) were adolescents or young adults under the age of 20 years; this age range is further analyzed as follows:

-	-	-	-	-	-	-	-	-	-	-
1	1	1	1	1	1	1	1	1	1	2
0	1	2	3	4	5	6	7	8	9	0
	1		1		3	4	1			1

There were no skeletal remains of young children apart from an isolated finding of one deciduous tooth (context 300). Only 7 adults (20%) were between the ages of 20 and 35 years. Sixteen (47%) were over 35 years old, and this group was equally divided between those just under 40 years and those who were more elderly.

Sex

Skeletal sexing was determined in 23 adults. Twenty-two were male. Only one (context 573) was regarded as female and in this elderly individual the evidence was not totally conclusive because the skeleton was incomplete, in particular there were no pelvic bones, the ends of the long bones were missing and the height could be determined.

In most cases it was not possible to be certain of the sex of the adolescents. This was partly because sexual characteristics were incompletely developed, partly because significant areas, particularly the pelvis, were missing. Most appeared to be male; in only two, both aged about 15 years were there features suggesting a female. The first (context 757) was of small stature (154-159cm) as compared with degree of dental development, but some 15 year old boys are of this height. the second (context 801) had bones of a generally slender build, but the remains were partial. In neither was there pelvic evidence.

Height

The height was estimated from the tables of Trotter and Glesep (1952) in 16 adult males. This ranged between 164cm (5 41/2) and 183cm (6ft) and averaged 172.5cm (5 8).

Radiography

The lower ends of the tibiae of 7 individuals were examined radiographically for residual evidence of periods of arrested growth in childhood, demonstrable as transverse linear opacities. After prolonged burial, details of cancellous bone structure are lost before those of the much more robust compact bone. Radiography cannot be expected to provide as much evidence as in the living or recently deceased. Moreover, even during life, these lines (Harris lines) which may be evident in youth or early adult life may later resorb or be modified by various stresses. Nevertheless, five adult tibiae do exhibit lines of arrested growth, varying from two to five in number; they are not strongly developed and are partially resorbed, nor do they conform to any particular pattern suggestive of seasonal under nutrition or winter ailments. Unfused epiphyseal regions of the adolescents were too damaged for radiographic examination to be worthwhile.

Cranial Index

In very few burials was the cranial vault intact, and even then it was sometimes deformed by post-mortem compression so no general evaluation of cranial indices could be undertaken.

Pathology

Infective and Degenerative Conditions

The dental condition was, in general, very poor even by the standards of the time. Periodontal recession was present throughout and was quite advanced in one youth age 16 years. In nine cases there were dental abscesses and commonly these were multiple; they are a reflection of the severity of the periodontal disease. Caries was present in ten individuals; usually this affected the cervical region of the teeth and followed periodontal recession. In one person there was hypercementosis of upper molar roots due to excessive mobility. Attrition of molar teeth, accompanied by the development of secondary dentine, is evidence of a coarse diet. Apart from the obvious neglect of dental hygiene, the degree of dental disease and the apparently early age of onset may point to a poor quality diet, perhaps lacking vitamin C but possibly including a certain amount of sugar. There were a few exceptions to this pattern, one 25 year old man (context 987) had good teeth, no caries and only slight attrition.

Apart from dental conditions the most prevalent disorder was arthritis. This was noted in 11 individuals; 8 were aged 40 or more, 2 were 30-35 years old. In eight this principally affected the spine, resulting in osteophyte overgrowth (lipping) of the bodies of the vertebrae, often with fusion of adjacent bones. All regions of the spine were affected, the most mobile areas, cervical and thoraco-lumbar maximally so. In 5 of these there was also evidence of more diffuse collagenous degeneration, affecting the bony attachments of tendons and ligaments. Calcification of these has produced exaggerated roughening and ridging at these sites, its degree also influenced by differential muscle bulk and its usage. This condition is also known as diffuse idiopathic skeletal hyperostosis (DISH); its was apparently most associated with considerable pain, stiffness and restriction of spinal movement. Sometimes several adjacent vertebral bodies were fused together, a condition known as bamboo spine (context 966, [photoarchive](#)). Osteoarthritis affected the acromio-clavicular joints in two cases. The metatarso-phalangeal joints of the great toes were involved in two men, with gross bony overgrowth in one (context 1007, [photograph](#)). The individual thought to be an elderly lady had moderate arthritis of the metacarpo-phalangeal joint of her right thumb; this was evidently rheumatoid arthritis and did not affect the larger joints. One elderly male had arthritis of the spine, acromio-clavicular and temporo-mandibular joints. It is noteworthy that, apart from minor lipping of joint margins there was very little

arthritic change in the major limb joints - hip, knee and shoulder in particular. This, together with characteristic features of DISH distinguish the arthritic patterns in this population from that seen in this country now. Cervical spondylitis is a common condition in the elderly nowadays, then it occurred at an earlier age and as part of a diffuse and gross degenerative condition.

One man had disease of the right elbow joint. This had caused overgrowth of bone and great distortion of joint contours (context 576, **photograph**). Movements would have been extremely painful and markedly restricted, the elbow being permanently flexed and incapable of extension. This was a suppurative arthritis, infective in origin, but not tuberculous. It may have been caused by a penetrating injury, for example by a thorn. Alternatively it may have been blood-spread from a focus elsewhere in the body, most probably from his gross dental abscesses.

Tumours

There was residual evidence of a tumour in only one case. The surface of a tibial shaft (an isolated find) was indented over an area 5.5 x 2.7cm, the edge of the depression being hypertrophied and raised. This was evidently due to pressure from a slow growing soft tissue tumour, possibly a fibroma or an enlargement (aneurysm) of an adjacent artery.

Fractures

The shaft of one 5th metatarsal had been fractured; this was probably caused by direct violence, such as a rock fall and it is not typical of a march fracture, a stress-fatigue lesion. One left 5th metacarpal shaft had been broken as the result of a blow, possibly in boxing. The surgical neck of one humerus had been fractured, probably as the result of a fall on the elbow; it had impacted and had healed in an almost perfect position. No deformity or disability had resulted from any of these fractures.

One elderly man had sustained a dislocation of his left ankle joint, tearing the tibio-fibular ligaments and probably fracturing the fibula at a higher level (this part is now missing). Following this there was an extravasation of blood between the tibia and fibula which subsequently became ossified, within which a new inferior tibio-fibular joint (or pseudarthrosis) formed. This now presents a most unusual appearance (context 957, [photographed](#)). A bony outgrowth (an exostosis) from the tibia articulates by an irregular toothed joint with a similar outgrowth from the fibula above the level of the ankle joint. Despite this attempt by Nature to restore the situation, there would have been gross permanent instability of the ankle joint and pain on walking.

Congenital abnormalities and variations

there are a number of anatomical variations but only one was sufficiently abnormal to have given rise to symptoms. In a 25 year old man the 5th lumbar vertebrae was in two parts, the body, pedicle and upper articular facets being separated from the laminae and lower articular facets by a joint on each side which, in life would have been cartilaginous (context 992, [photographed](#)). This development abnormality, spondylolisthesis, results from each side of the neural arch having two ossification centers instead of one, and these do not fuse. The bones are usually held in place by the cartilage and by fibrous tissue. Sometimes asymptomatic, it is commonly associated with low back pain. As age advances the two parts may separate because of the very considerable forces transmitted through this region,; untreated this would produce disability.

Other variations were noted in single individuals apart from the relatively common woriman bones, most prevalent in the lambdoid sutures. There was a persistent metopic suture in the frontal bone of the skull of a 25 year old man. In another young man the arch of the atlas vertebra had remained ununited in the midline posteriorly and in a more elderly person the groove for the vertebral artery on the upper surface of the atlas was bridged over by a spur of bone extending to the posterior arch from the lateral mass. One 35 year old man had bilateral mandibular torus formation lingually between the canine and first molar teeth, probably a congenital and hereditary condition. The left femur of an elderly man had a supracondylar spur of bone postero-medially, extending upwards from the lower insertion of adductor magnus to form a boundary for the opening

through which the femoral artery passed; the right femur is damaged and it is not possible to determine whether this feature was present bilaterally.

General Conclusions

These burials evidently represent a selected group. It is possible that one individual was an elderly woman but the evidence for sexing of this skeleton is not conclusive; apart from that, all other burials of adults were of men. There are no children under the age of 10 years. There is an unusually large group of adolescents, the sexing of whom is largely indeterminate for the reasons given. There are few individuals in the 20-35 year age group, yet a relatively large number aged approximately 35-45 years.

Apart from one person, there is no evidence that these people were of a high social standing. Their dental hygiene was particularly bad even for that era, their diet was generally coarse, as was usual. Their muscular development, where this could be studied, was quite strong and suggestive of labouring work, walking, stooping, lifting; the prevalence of spinal arthritis supports this pattern of activity. The frequency with which spinal arthritis was associated with collagenous degeneration of tendons and ligaments probably reflects cold, damp working and living conditions. It is noted that amongst the isolated finds, there is a pair of feet, not of itself unusual in a disturbed site; however the presence of five left adult great toe metatarsals in one context present an enigma.

References

- Trotter, M & Glese, G.C. (1952) Estimation of stature from long bones of American Whites and Negroes. *Amer. J. Phys.Anthrop.*, Washington, 10: 463-514
- Wilkinson, J.L. (1980) Problems of analysis and interpretation of skeletal remains, in *Anglo-Saxon Cemeteries*, 1979 B.A.R. Series 82,228.

1988 and 1990 Excavations

SUMMARY OF FINDINGS FROM THE CHOIR OF THE CHURCH AND NORTHERN EXTENSION OF THE NAVE

Introduction

My first report on skeletal remains within the Chapter House was mostly of separate burials in a few identifiable graves .

This second study was in marked contrast to the first. Total numbers were much greater, many remains were less easily identifiable as from discrete graves. Many finds were either of very incomplete skeletons or very partial remains. There was often considerable admixture and variability: in presentation one standard box might contain remains from up to 25 contexts (Box 31) or one context (1371) might be in up to 6 boxes. In addition there was skeletal material not buried in situ but assumed to be from a demolished charnel house (context 1631, 8 boxes). Such factors conduced to greater difficulty of interpretation.

Numbers of individuals

In estimating total numbers, minor remains are excluded and efforts have been made to avoid overlap. The possibility of overlap in a few cases cannot be completely ruled out: conversely, exclusion of some material probably means that the estimate is conservative. There are 35 relatively complete skeletons; the majority are represented by partial remains. Included in the latter are the charnel pit deposits (mostly long bones and skulls). Altogether there are considered to be 193 individuals, of

which 142 are adults, 51 are juvenile (under 20yrs.). Of the total, 163 are in situ burials, 30 are from the charnel house secondary burial. Detailed individual conclusions are set out at the end of context reports: these are briefly aggregated here.

The basis for estimation of numbers, as related to contexts, is listed below. Relatively complete skeletons have context numbers in bold print, partial remains are in light print. Unless otherwise stated, each context represents one individual: the order is only related to box number presentation, and corresponds to the order in the report. The context numbers which are excluded here are not considered sufficiently representative to betoken an individual.

1701, 1702, 1826, 1827, 1825, 1830, 1833, 1945, 1847, 1850, 1885, 1818, 1823, 1852, 1856, 1858, 1866, 1887, 1881, 1869, 1892, 1889 (2), 2096, 2098, 2184, 2185, 2179-fill of grave-(6), 2045 (3), 1889 (4), 1886, 1902, 1905, 1914, 1916, 1932, 1945, 1955, 1893 (2), 1527 (5), 1678, 1639, 1738, 1618 (3), 1664 (2), 1801, 1804 (2), 1807 (3), 1809 (5), 1819 (6), 1822, 1929 (2), 1837, 1870 (3), 1862 (6), 1872 (2), 1874 (6), 1885 (2), 1889 (2), 1917 (3), 1941, 1943 (2), 1907 (6), 1967 (8), Box 51- no context number- (4), 1371 (8), 1371 (11), 1382 (10), 1388 (2), 1389, 1394, 1401, 1631-charnel-(30)(27 from skulls, 3 additional juveniles from long bones)

Individual Ages and Sex

Juveniles

The age range of 51 sub-adults is as follows:											
Age	-1	-2	-4	-6	-8	-10	-12	-14	-16	-18	-19
Total	4	-	3	5	4	7	5	6	8	8	1

It is not often possible to determine the sex of young children; of 17 adolescents (ages 12-19yrs.) that were sexed,9 were male, 8 were female.

Adults

The age range of 119 adults who were sexed and aged is as follows:								
	-25	-30	-35	-40	-45	-50	-55	-60
Male	16	14	18	23	4	-	2	1
Female	16	9	3	10	3	-	-	-
Total	32	23	21	33	7	-	2	1

22 adults (11 male, 11 female) were sexed but not aged. One adult was neither sexed nor aged.

Mortality

It is assumed that the majority of the persons here represented were resident in the local community. It will be interesting to obtain and compare mortality rates for similar medieval rural communities. Today, in undeveloped countries there is a heavy mortality in the 'under fives', influenced by malnutrition and local endemic diseases. Here we see a more general spread under the age of 20yrs., the peaks being -18yrs. and -19yrs. and possible causes for this are now open for consideration.

It will be interesting to plot the location of child burials: in the order in which the contexts were presented there does appear to be some clustering, as can be noted in the tables at the end of this report. There was very little evidence of burials of the stillborn or neo-natal: perhaps it was not customary to bury these in consecrated ground. Standards of midwifery and obstetric knowledge being relatively poor, neonatal mortality must have been higher than evidenced here.

There is also a high mortality in the 20-25yr. age group. The ageing of this group did not rely entirely upon dental attrition but is based on many criteria. Included here are degrees of fusion of late epiphyses such as the medial end of the clavicle and late secondary epiphyses of the hip bone such as iliac crest and ischial tuberosity, development and fusion of the sacrum, vertebral body epiphyseal plates, the appearance of the pubic symphysis.

Dental attrition assists in ageing up to 40yrs., but beyond this age the general criteria are less reliable.

There are marked contrasts with the Chapter House series: for example, a higher mortality in the 25-35yr. groups

Body Height

The body height was determined from the tables of Trotter and Gleser (1952) in 58 adults. This ranged between 157 and 182cm. for males and between 156 and 166cm. for females.

The body height of 32 adult males are as follows (<1cm. ignored):

-167	-170	-173	-175	-178	-180	-183 cm.
(5'6")	(6'7")	(5'8")	(5'9")	(5'10")	(5'11")	(6'0")
3	8	6	5	2	5	3

The body heights of 22 adult females are as follows: (<1cm. ignored)

-157	-160	-162	-165	-167
(5'2")	(5'3")	(5'4")	(5'5")	(5'6")
4	5	5	6	2

Physique and Socio-economic factors

Of those evaluated for apparent general physique, as judged by robust or slender bone structure, and the strength of muscular tendon insertions, 19 out of 27 were regarded as of robust physique. Their muscle tendon markings were well developed, suggesting of strong sustained physical activity.

Tentative views may be gained as regards socio-economic factors when general physique is considered alongside levels of dental hygiene. Of 22 thus studied, 14 were regarded as 'working class', used to manual labour, 8 appeared to be of an 'upper class', associated less with manual labour and more observant of hygiene.

Cranial Morphology

In most individuals the skull vault was incomplete, damaged, fragmented or if relatively complete, distorted by post-mortem pressure. In only 25 cases was it possible to study cranial indices. These were:

Dolichocephalic 12 : Mesocephalic 8 : Brachycephalic 7

Pathology

Infective and Degenerative Conditions.

The standard of dental hygiene was generally very poor. Periodontal recession was very common and particularly advanced in 18 individuals. As a result of poor hygiene and gum recession, dental abscess formation occurred in 16 cases; sometimes multiple abscesses were present and this was responsible for the loss of teeth. Caries was relatively uncommon by modern

standards, only noted in 6 persons: and this is to be expected where the sugar content of the diet is low. Periodontal recession exposes the neck of teeth and this was the usual site for caries when present. Breakage of teeth, particularly of premolars, resulted from cracking hard objects, probably nuts: some caries could be expected to follow this and would not necessarily be separately recorded. Attrition of molar teeth was similar in degree to that seen in the first series, indicating a coarse diet: in a few cases the diet appeared to have been more refined. A few individuals had marked wear of the cutting edges of incisor teeth: whilst this can result from biting tough food, unusual incisor wear may be associated with occupation e.g. leather workers, holding a strap with the teeth.

There was one case of suppurative arthritis of a metatarso-phalangeal joint. This may have followed a penetrating injury, such as by a thorn. A similar case was seen in the Chapter House series and suggests that the individuals may have been unshod.

Osteo-arthritic changes in joints was relatively common. The distribution in order of frequency was as follows:

Spine (11), costo-vertebral (transverse) joints (7), Knee (3), metatarsophalangeal (3), hip (2), acromioclavicular (2), sternoclavicular (1), shoulder (1), carpometacarpal (1), sacroiliac (1), tarsal (1)

Diffuse idiopathic skeletal hyperostosis (DISH) was noted in 6 cases: ossification of tendon and ligament attachments, accompanied by spinal lipping sometimes involving fusion of adjacent vertebrae but without the disc degeneration of arthritis. It is interesting to note that this is a much lower incidence than was found in the adults from the first series, burials in the Chapter House, many of which, it is believed, were monks. There is considerable interest at the present time in an apparently high incidence of DISH in Priories, and possible reasons for this are under investigation. One modern theory relates to a high fish diet. The nature of DISH was discussed in the first report. In one individual (1829) the coraco-clavicular ligament must have become ossified and then a very unusual type of joint formed here. There were additional isolated examples of ossification in tendon attachments, such as a calcaneal spur or a lipping of the olecranon of the ulna at the attachment of the triceps tendon, not uncommon in modern times.

In only 3 cases was there obvious evidence of Schmorl's nodes, central protrusion of intervertebral discs into the adjacent surfaces of vertebral bodies. Recent investigations reported in the Journal of Anatomy, have suggested that there was a higher incidence of this condition in medieval than in modern times (Fitzpatrick et. al., 1984, 1986). It should be noted, in this regard,

that in this series vertebral bodies were not well preserved and often were absent: from the 30 bodies from the Charnel House there were only 13.

One individual had a 'squatting facet' on the anterior border of the lower articular surface of the tibia, at the ankle joint. This is quite a common finding amongst some tribal African and Eastern cultures in which squatting is a common posture. It is an uncommon finding in this country.

There were 4 cases of Paget's disease, in which the skull vault was very markedly thickened. It did not appear to have involved the post-cranial skeleton.

Trauma.

There was little evidence of injury. One 40-year old lady (context 1945) had sustained a fracture of the right ulna which had healed without deformity. A 45-year old lady had fractured an ulna which had united with some overlap, angular and rotational deformity. We do not know whether the radius on this side had also been fractured, if so, it is not easy to fix the bones in such a way as to avoid residual deformity. The functional end result in this case was probably fairly good (context 1822).

There was one other fracture, of the midshaft of the clavicle, a bone which heals very readily in virtually all cases, but in this person had not done so (**Plate 24**). Healing had begun and there is no evidence that it would not have continued. The patient, a youth of 16 years, died approximately 7-10 days after the accident. It is probable that there other injuries, possibly to internal organs which caused death (context 1881).

Of particular interest is a case of trephining of the parietal bone (context 1893). The patient evidently survived the operation because the cut edges healed and the spongy diploe are not visible here. This also excludes the possibility of a post-mortem

artefact, as does the lack of internal splintering. It is particularly interesting that there are two holes and not just one. The method used was that of cutting out a roundel or possibly the use of a single burr drill. Well known in ancient civilizations ranging from Egypt to South American tribes and in Tibet, only about 12 cases are recorded from archaeological sites in this country and these were mostly prehistoric, only 3 Norman and later. The operation is known to have taken place in France in the 13th. century, and in this country in 16th. and 17th. centuries. As a finding from the medieval period it must be very rare. There appears to be only one recorded find from Wales and that was pre-Norman (Brothwell). It is intended to investigate this matter further.

Congenital abnormalities and Variations

Most of these involved either the skull or vertebral column.

Skulls. There were 12 cases of persisting metopic sutures. The average incidence is 2% for most populations. A high incidence may perhaps indicate a degree of in-breeding. Small accessory sutural (Wormian) bones are not uncommon: in 5 cases Wormian bones were particularly evident: in one individual there were 10 such bones in a row in the occipito-parietal sutures (context 1889). Supraorbital foramina in place of the supraorbital notch were quite common: 5 on the left side, 4 on the right, 6 bilateral. There was one case of foramina in the orbital roofs (orbital plates of the frontal bone).

Jaws and Teeth there was congenital absence of the 3rd. molars in 7 cases, absence of other teeth in 2, ectopic (extra) teeth in 3. There was one instance of fusion of the crowns of premolar teeth (**Plate 34**). In 3 mandibles a torus was noted.

Vertebrae. Imperfect fusion: 1 unfused arch of the atlas vertebra; 1 unfused and bifid spine of a 5th. lumbar vertebra; 1 spondylolisthesis of 5th. lumbar vertebra (a case also noted, **photographed** and described in the Chapter House series); 1 unilateral spondylolysis of the 5th. lumbar vertebra (an unfused line between upper and lower articular facets on one side of the arch but no displacement). The incidence of spondylolysis in the medieval period was about 5%, less common unilaterally than bilaterally (Waldron, 1991).

Unusual fusion between vertebrae: 2 sacralization of the 5th. lumbar vertebra (fused to the sacrum); 1 congenital fusion between two thoracic vertebrae; 2 cases of a bony arch spanning the vertebral artery in the groove on the atlas..

Others. Scapula: 2 suprascapular foramina, an arch spanning the suprascapular groove. Sternum: 1 fused manubrio-sternal joint. Femur: 1 hypotrochanteric fossa, with a 3rd. trochanter. Hip bone: 1 case of unusual ossification of the Y-shaped acetabular cartilage with multiple accessory centres of ossification (os acetabuli).

Note: Unusual congenital anomalies or pathological conditions have been photographed.

References

Brothwell D.R. (1972), 'Digging up bones', 126, Trustees of the British Museum, London.

Fitzpatrick K., Bruce M. and Saluja G. (1984), 'Evidence of Schmorl's nodes in medieval Aberdonians' and 'Osteological evidence of Schmorl's nodes in two historic British populations', J. Anat. 138, 579 & 600, also J. Anat (1986), 145, 87-96.

Waldron H.A. (1991) 'Variations in the prevalence of spondylolysis in early British populations', J. Roy. Soc. Med. 84, 547-549.

The 1988-1990 excavations

Summary Table

Key.

M=Man. F=Woman. C=Sub-adult(<20yrs). C(m)=male child. C(f)=female child. Ad=Adult, not aged.

No.	Age	Sex	Height (cm.)	Features
1701	30	M	174.5	Absent 3rd. molars. Femoral bowing
1702	<1	C		
1826	40	M	169.4	Periodontal disease, Dental abscess, Arthritis.
1827	-40	F	162	Periodontal disease. Dental abscess. Paget's disease
1825	22	F	156.3	Mesocephalic. Wormian bones. Unfused arch of atlas. Absent 3rd. molars
1830	40+	F	163.9	Brachycephalic. Metopic suture. Periodontal disease. Caries. Dental abscess. Arthritis.
1833	50+	M	168.3	Brachycephalic Periodontal disease Caries. Dental abscess. DISH.
1945	40+	M	173.8	Periodontal disease. Dental abscess. Cervical spondylosis (arthritis). Calcaneal spur
1847	30	M	174.1	Absent 3rd. molars. Arthritis.
1850	30+			
1885	-30	M		Dolichocephalic. Absent 3rd. molars
1818	30+	M		

1823	30	F	157.5	Dolichocephalic.Femoral hypotrochanteric fossa,3rd. trochanter Suppurative arthritis metatarso-phalangeal joint
1852	30	M	175.9	
1856	-16	C(f)		Dolichocephalic.Wormian bones
1858	25	M	181	Dolichocephalic. Absent 3rd. molars
1866	60	M	173.8	Mandibular tori.Periodontal disease.Dental abscess.Fused carpo- metacarpal joint
1887	40	M	164	
1881	16	C(m)	175	Unilateral spondylolysis.Periodontal disease
1869	40	F	157.2	Brachycephalic.Sacralization L5 vertebra.DISH.Periodontal disease.Dental abscess
1892	30	M	176	Periodontal disease.Dental abscess
1889	35	F		Mesocephalic.Right supraorbital foramen.Periodontal disease
..	25	M		Brachycephalic.Multiple Wormian bones.Bilateral supraorbital foramina.Metopic suture.
2096	23	M	178.5	Mesocephalic.Wormian bones.Right supraorbital foramen. Spondylolisthesis.Fused manubrio-sternal joint.Schmorl's nodes
2098	35	M	173	Absent 3rd. molar&premolar.Incisor attrition.Periodontal disease
2184	17	C(m)	176	Mesocephalic.Metopic suture.Wormian bones.Recent fracture clavicle.
2185	25	M	169	Brachycephalic.Metopic suture.
2179	25	M		General for 2179.One of each: dolichocephalic, metopic
..	30	M		suture.Ossification supraspinous ligament(DISH).Sacralization L5
..	45	M		vertebra.Tibial squatting facet.Dental abscess.
..	25	F		
..	30	F		
..	7	C		
2045	Ad.	M		
..	Ad.	F		

..	17	C(m)		
1889	20	F		Periodontal disease
..	50+	M	166.6	Paget's disease
..	17	C(m)	174.5	Metopic suture.Ectopic canine tooth
..	25	F	158.4	
1886	35	M	173.4	Brachycephalic.Ectopic unerupted incisor teeth.Periodontal disease
1902	30	M	182	Mandibular torus.DISH.Vertebraal fusion.Periodontal disease.Dental abscess
1905	28	F	160	Dolichocephalic.Metopic suture.Dental abscess.Periodontal disease.
1914	40	F	163	Caries.Periodontal disease
1916	30	F	165	Dolichocephalic.Impacted molar.Early arthritis.
1932	30	M	180.4	
1945	40	F	161	Arthritis.Old fractured ulna.
1955	-30	M	170.8	Absent 3rd. molar
1893	20	M		Trephine holes in skull. Caries.
..	25	M		Right supraorbital foramen
1527	30	M		
..	20	F		
..	6	C		
..	10	C		
..	15	C		
1678	Ad.	M		
1639	30	F		Dental abscess
1738	18	C(f)		
1618	40+	M		
..	30+	M		
..	25+	F		

1664	30	M		
..	25	F		
1801	40	M		DISH
1804	5½	C		
..	10	C		
1807	3	C		
..	11	C		
..	Ad.	F		
1809	4 ½	C		
..	5 ½	C		
..	10	C		
..	13	C		
..	Ad.	F		Metopic suture
1819	40	F		Dental abscess
..	30	M		
..	10	C		
..	13	C(f)		
..	15	C(m)	165.8	
..	8	C		
1822	45	F	158.5	Fractured ulna,healed with deformity
1829	40	M		Paget's disease.DISH.Suprascapular foramen.
..	-40	M		
1837	15	C(m)		
1870	40+	F	166.2	Arthritis
..	6	C		
..	8 ½	C		
1862	20	M	182.7	Unfused bifid spine 5th. lumbar vertebra
..	35	M	180.4	

..	Ad.	F	162.3	
..	<1	C		
..	4	C		
..	Ad	M	174	DISH.Periodontal disease.
1872	<1	C		
..	30	F	162	
1874	17	C(f)		
..	40	M		
..	10	C		
..	12	C		Unusual ossification of acetabulum
..	15	C		
..	17	C		
1885	Ad.	M	179	
..	35	F		
1889	20	F		
..	25	M		
1917	13	C(m)		
..	25	F		
..	20	M		
1941	20	F	165.9	
1943	Ad.	F		
..	40	F		
1907	<1	C		General (1907) one of each-Mesocephalic. Bilateral supraorbital foramina.Absent 3rd. molar.Arthritis. Caries. Dental abscess
..	9	C		
..	25	M	168	
..	40	M		
..	20	F	156	
..	25	F	161	

1967	40+	M	168.5	Mesocephalic.Bilateral supraorbital foramina.Arthritis
..	35	M		
..	25	M		
..	25	F	166.2	Dental abscess
..	8	C		
..	14	C(f)		
..	16	C(f)		
..	Ad.	M		
Box51	Ad	M	169.4	
..	Ad	M	167.6	
..	Ad.	F	165.2	
..	Ad.	M		
1371	20	F		
..	25	M		
..	40	M		
..	40	M		
..	40	M		
..	Ad	M		
..	4	C		
..	12	C		
1371	25	M	179.4	
..	30	M	180.7	
..	35	M	169.4	
..	40	M		Arthritis. Schmorl's nodes
..	25	F		
..	Ad	F	161.3	
..	Ad	F		
..	Ad	?		

..	8	C			
..	14	C			
..	18	C(m)			
1382	25	M			
..	35	M			
..	35	M			
..	Ad	M			
..	Ad	M		Left supraorbital foramen	
..	Ad	F			
..	18	C(f)		Dolichocephalic.Bilateral supraorbital foramina	
..	Ad.	F			
..	Ad	F			
..	12	C			
1388	35	M		Bilateral supraorbital foramina	
..	14	C(f)			
1389	40	M		Periodontal disease. Arthritis	
1394	35	M		Periodontal disease. Dental abscess. Arthritis.	
1401	40	M		Periodontal disease. Caries	
1631	45	M	171.7	Dolichocephalic.Left supraorbital foramen	}These heights correspond }to the sex but not }necessarily to these }individuals. }Charnel House long bones }and skulls were unrelated
..	40	M	168.7	Dolichocephalic	
..	20	M	174.5	Dolichocephalic.Metopic suture	
..	35	M	171.5		
..	30	F			
..	40	M			
..	40	M		Right supraorbital foramen	
..	35	M			
..	35	M		Metopic suture.Left supraorbital foramen	
..	35	F	162.5		

..	40	M		
..	40	F	159.8	
..	25	F		
..	40+	M		Paget's disease
..	35	M		Left supraorbital foramen
..	30	M		
..	35	M		
..	45	M		
..	45	F		
..	30	F		Mesocephalic
..	35	M		Dolichocephalic
..	40	F		Mesocephalic. Metopic suture
..	40	F		
..	25	F		Metopic suture. Bilateral supraorbital foramina.
..	40	M		Brachycephalic
..	40	M		Left supraorbital foramen
..	40	M		
..	12	C		}
..	16	C		}Charnel House Skulls
..	19	C		}

Summary of Finding from the 1997 Excavations (Choir and graveyard)

Introduction

This is my third report, previous accounts relate to the 1984-6 and 1988-90 excavations. The first twenty nine burials were lifted: of these 24 have been examined. Their total individual representation was variable, from a few bones to an almost complete skeleton. In six graves there was more than one body. Subsequent skeletons are often represented by 5-30% of a body, up to 3 bodies might be present in one numbered burial: this has a considerable bearing on the amount of detailed information that can be acquired, for example in the regional distribution of arthritis, or calculation of cranial indices.

Numbers and sex of individuals

The total number is 111. There were 10 (unsexed) children under the age of 15yrs, the youngest aged 1½yrs. Of 6 adolescents (15-19yrs) 4 were male, 2 female. Of 95 adults 72 were male, 17 female and 6 were of indeterminate sex.

Age structure

In 29 individuals their bone samples were very incomplete: the age was regarded as adult, but more precise detail was indeterminate. Ages were determined for 78 bodies. For juveniles this related to tooth and bone development. For children accurate tables are available for determining age from the distance between epiphyseal plates, where a long bone is intact. The degree of development of deciduous and permanent teeth and their eruption are reliable criteria. As age advances the major epiphyseal plates fuse at known dates, then between 20 and 25yrs. secondary epiphyseal plates on pelvic crests and tuberosities, vertebral bodies and clavicle unite. The pubic symphyseal surface changes between 18 and 30yrs, and later. Age

after 20yrs. is based considerably on dental attrition but a proviso here is that this will depend on the degree of coarseness in the diet. As age progresses there may be progressive dental loss. The degree of skull suture fusion is of some assistance but a variable factor. As age advances the degree of arthritis becomes more evident. It is generally difficult to give detailed estimates of age over 45yrs.

Tables

Total											
Age	5	10	15	20	25	30	35	40	45	45+	
Adult?											
No.	3	7	-	6	9	14	13	12	9	5	29

Children & adolescents														
Age	2	3	4-5	6	7	8	9	10	11-14	15	16	17	18	19
No.	1	2	--	2	1	1	1	2	--	1	1	2	1	1

Body Height							
5'5"	5'6"	5'7"	5'8"	5'9"	5'10"	5'11"	6'0"
							6'0"
							6'1" .6'2"
Males							
2	2	4	5	11	5	4	5
1							1
Females							
4	2	1	1				

The average male height is not inconsiderable. The peak (27.5%) is at 5'8½" to 5'9"; 67.5% are over 5'8" (5.8½" to 6'2). Taken together with limited information on cranial indices, this is probably beyond a Celtic pattern. One assumes that the Priory would attract incomers from a wide geographical area. Was there any Norman influence ?. With a few exceptions the body build was robust.

Congenital features

Skull.

The cranial index was determined in 8 bodies. The results were; brachycephalic - 1, mesocephalic - 3, dolichocephalic - 4. It was noted in the last previous report that dolichocephaly was the most common form.

Only one persistent metopic suture was seen: this contrasts with a much higher incidence in the last report. But it must be noted here that in this series there were relatively very few intact frontal bones survived.

Supraorbital foramen (or foramina) were noted in 4 frontal bones.

Unerupted or absent 3rd. molars : 5 individuals.

Accessory teeth: 3 bodies

Mandibular torus: 2 bodies

Spine.

One one individual the atlas vertebral arterial groove was roofed over to become a canal.

Schmorl's nodes were noted in one vertebral body, but may have been more frequent: relatively few intact vertebral bodies were represented throughout. The incidence (as previous noted), is usually higher in medieval skeletons.

Pathology

Skull.

Hyperostosis frontalis interna, 1 case, is an overgrowth on the inner aspect of the frontal bones, of unknown cause.

Cribrra orbitalis, 1 case, porosity of the orbital roof, signifies malnutrition, particularly a shortage of iron.

Birth injury: 1 case of curious flattening of one side of the frontal bone, present since a very early age, perhaps during birth, or early infancy, when the skull is very thin.

Teeth.

Periodontal disease and alveolar recession was very evident in 17 bodies: some degree of it was usually present over the age of 20yrs. Its incidence would have been higher had the population been older.

Dental abscess, 6 cases, commonly follows persistent neglect of dental hygiene and often accompanies tooth degeneration and loss.

Caries, 4 cases, uncommon in relatively sugar-free diets, was usually in the neck of the tooth, accompanying periodontal recession.

Dental attrition was often not severe, suggesting that with many the diet was very coarse.

Syphilis

A tibia (burials 70/74) and a femur (27) have swellings due to syphilitic periostitis (see below).

Trauma.

Fracture of the tibia, at the junction of upper three quarters and lower quarter, associated also with a fracture of the upper end of the fibula. This tibial fracture is notoriously slow to heal, partly due to blood supply and lack of local muscle attachments. It had healed very soundly with ½" shortening and minimal rotation: it must have been well splinted and rested. (for **photograph**)
Crush fracture of the lower thoracic spine. This was unusual and quite severe. The upper two vertebrae are fused at body and articular processes, though the disc has partly survived; the lower two have bodies that have been pushed into one another, with vertical crush and rotational deformity. There is also a severe crush fracture of a lumbar vertebral body in an elderly female.

DISH and Arthritis

Diffuse idiopathic skeletal hyperostosis (DISH) was present in 6 cases, with ossification of tendon and ligament insertions and usually vertebral lipping. It was not gross in the sense that it had not caused spinal fusion with ossification of anterolateral ligaments, but it was occurring in fairly young individuals and this might have followed had they lived longer. It was apparently not uncommon in monastic communities and is thought to be related to a high fish diet. Nowadays it is seen most commonly in Japan.

Osteoarthritis was noted in 12 bodies. The incidence was as follows:

Vertebral bodies (7), costo-vertebral (6), atlanto-axial (2), sacroiliac (1), iliolumbar (1), shoulder (1), radio-ulnar (1), tibio-fibular (1), knee (2), head of 1st. metatarsal (1).

This examination has extended and amplified previous work. There are relatively few females, particularly in the later numbered burials. On the possibility that burials within the Choir may represent Priors, Novices and perhaps a local high social class, further correlation may be of interest.

Historical note on syphilis.

There are two opposing views about the antiquity of syphilis. One is that the sailors of Columbus brought it to Europe where it was spread throughout Italy in 1493 by soldiers of Charles VIII, then rapidly through Europe. The other view is that it existed at much earlier times, was referred to in Egyptian and Assyrian inscriptions and there is evidence of it in mummies. The outbreak was virulent in the Middle Ages . It was not then known to be of venereal origin.

**The
Photographs**

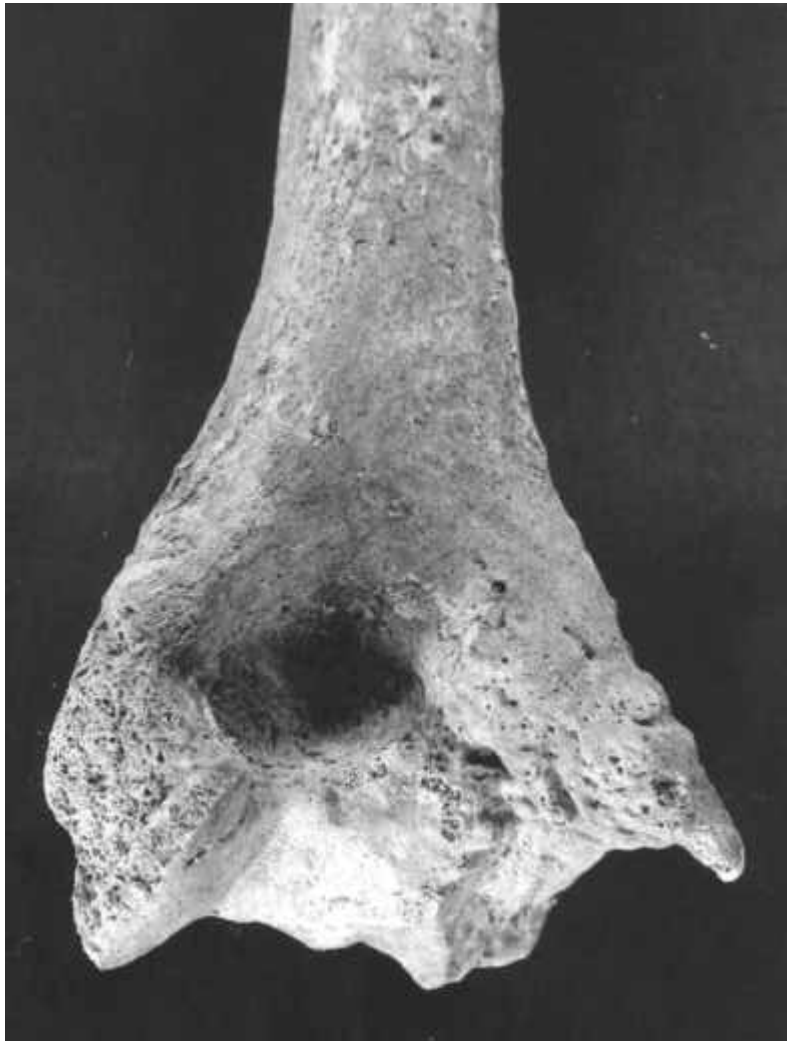

Plate 1 Context 576:
Lower end of right humerus from below



Plate 2 Context 576:
Right humerus, radius and ulna (elbow joint) from front

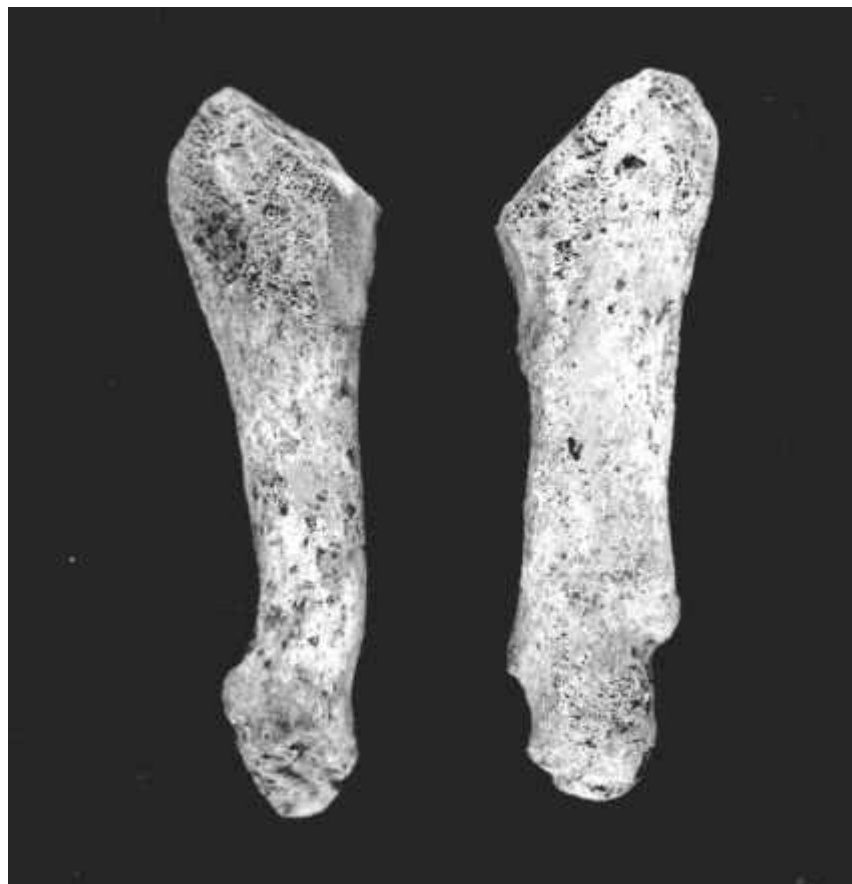


Plate 3. Context 595: Left 5th metacarpal (on right of photo) showing results of old fracture. Compare with normal right 5th metacarpal (left of photo) – this is more slender.

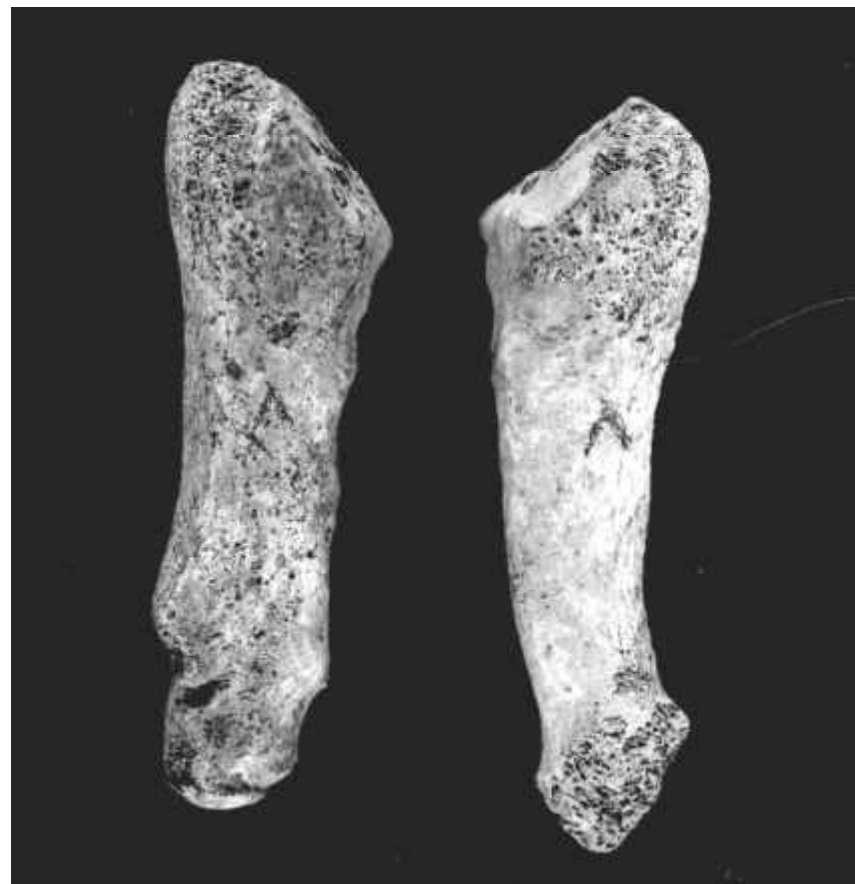

Plate 4. Context 615: The 5th left metatarsal (left of photo) has been fractured (also Xrayed). Compare with normal 5th right metatarsal (right of photo)



Context 754:

Plate 5 [Left] Left femur showing exaggerated tendon insulation with the linea aspera (due to DISH)

Plate 6 [Above] Left hip bone, note the roughening and lipping of the muscular attachment to the iliac crest (DISH).



Plate 7 Context 957: Pseudarthrosis of left tibia and fibia viewed from behind.

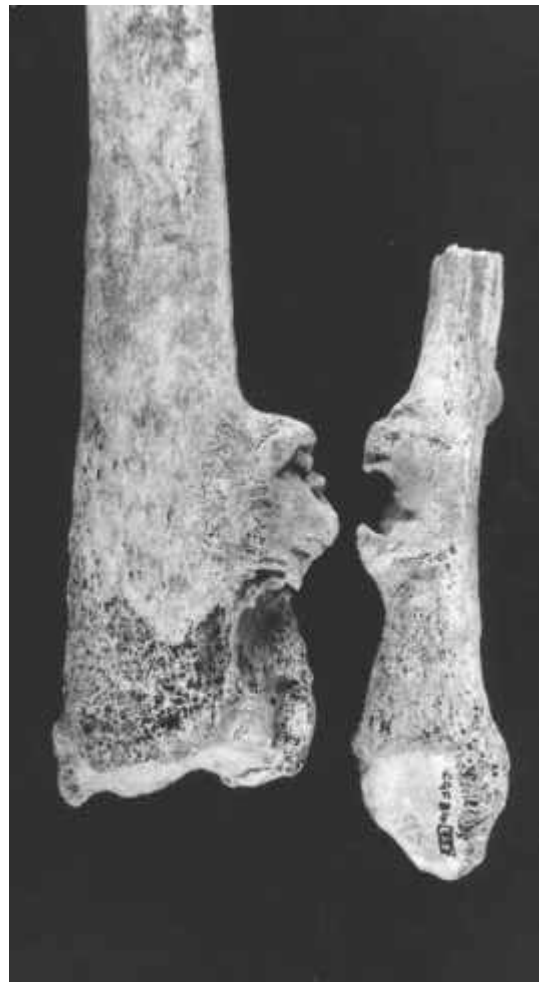

Plate 8. Context 957: Pseudarthrosis of left tibia and fibia – these have been separated to demonstrate the irregular toothed surfaces of the false new ‘joint’.

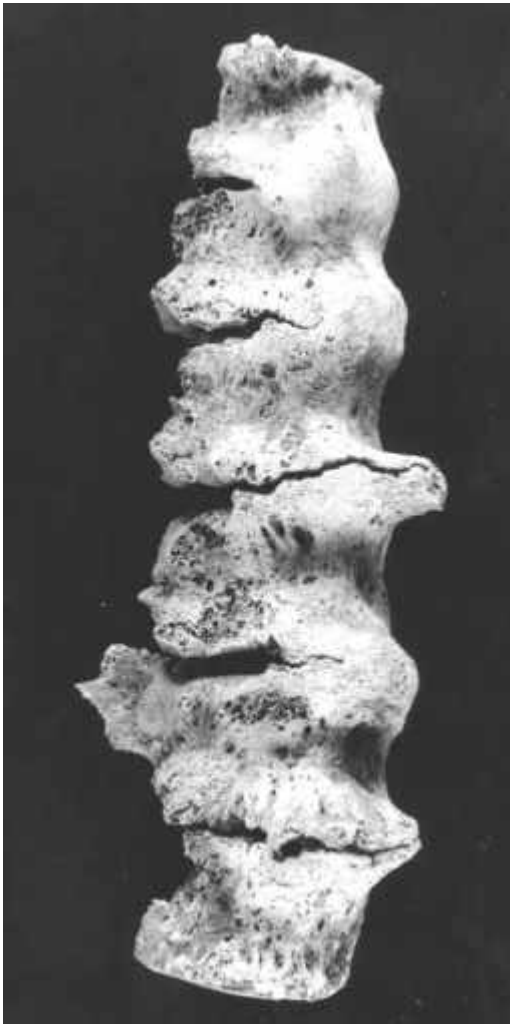


Plate 9 Context 971: 'Bamboo Spine'. Fusion of thoracic vertebral bodies.



Plate 10 Context 971: Fusion of cervical vertebral. Fusion of lumbar vertebral.

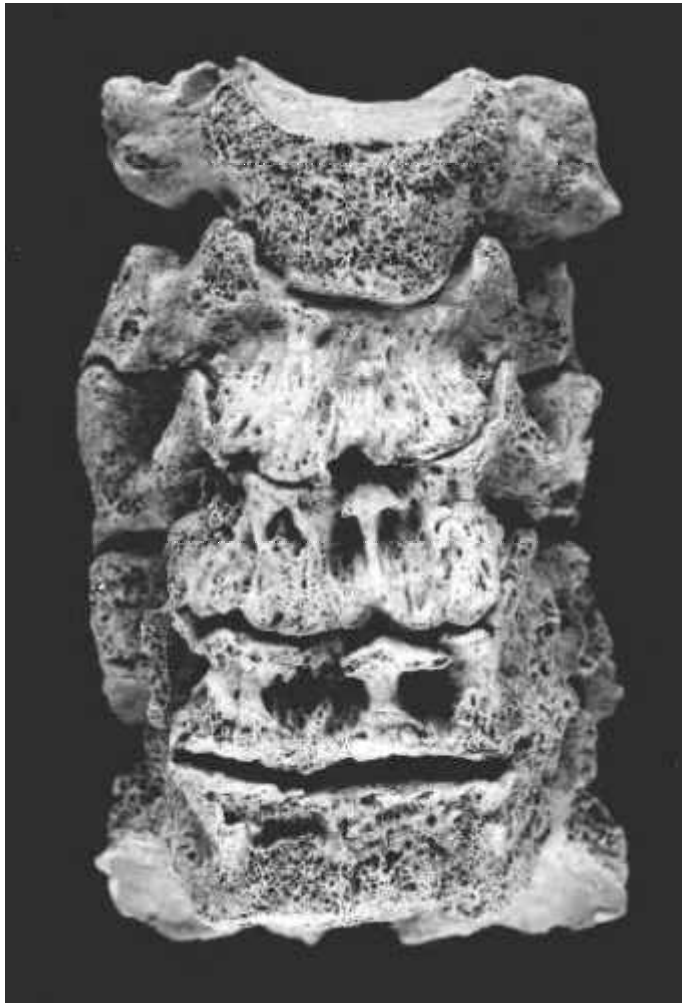
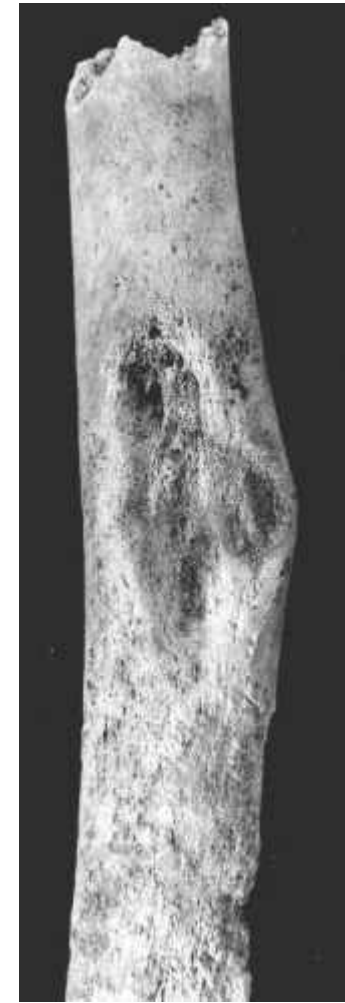
Plate 11 Context 972: [left] Early fusion of cervical vertebræ - ('spondylitis').

Plate 12 Context 980: [right] Isolated tibial shaft showing indentation and overgrowth of its margins due to external pressure from a soft tissue growth.



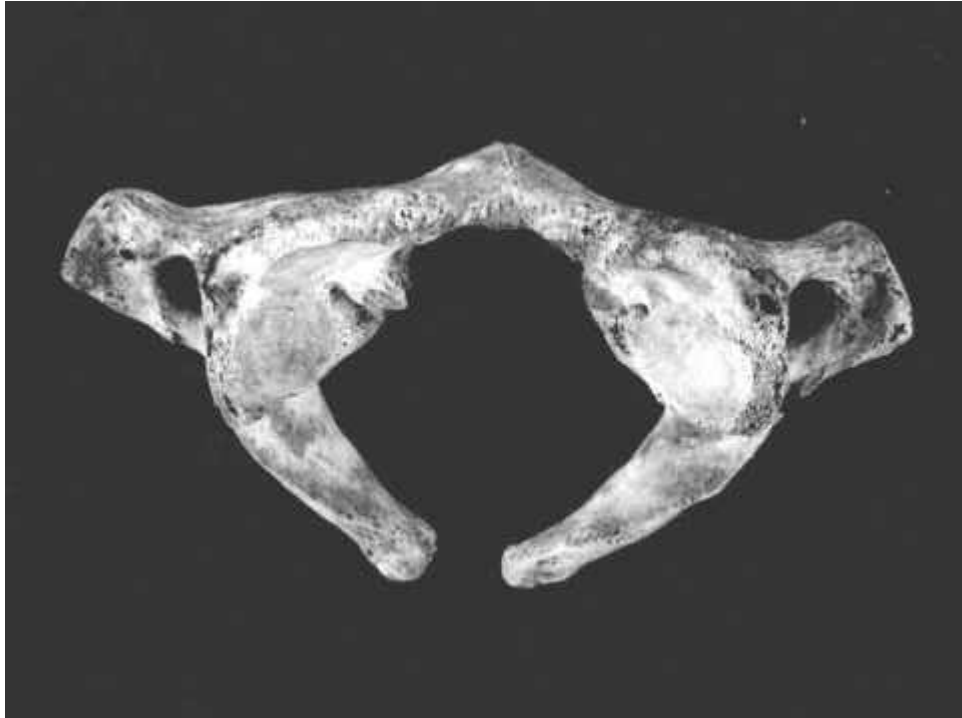
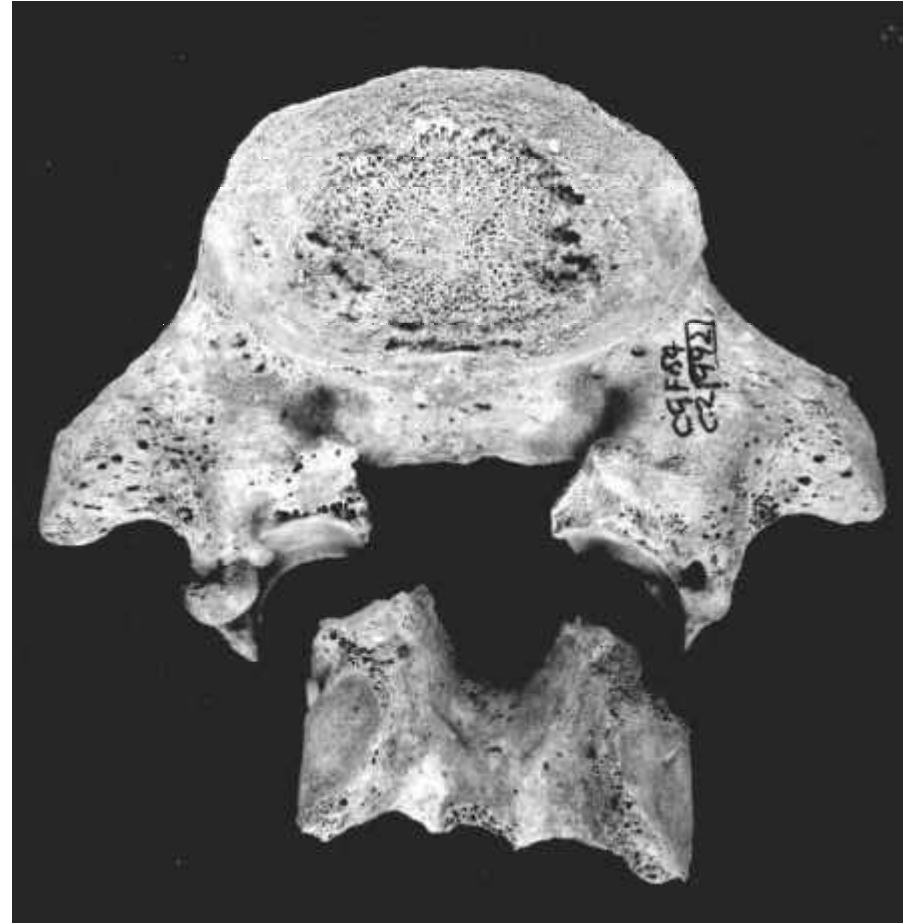

Plate 13 Context 987: [above] Atlas vertebra, failure of fusion of the posterior arch.

Plate 14 Context 992: [right] 5th lumbar vertebra showing a congenital anomaly, spondylolisthesis.



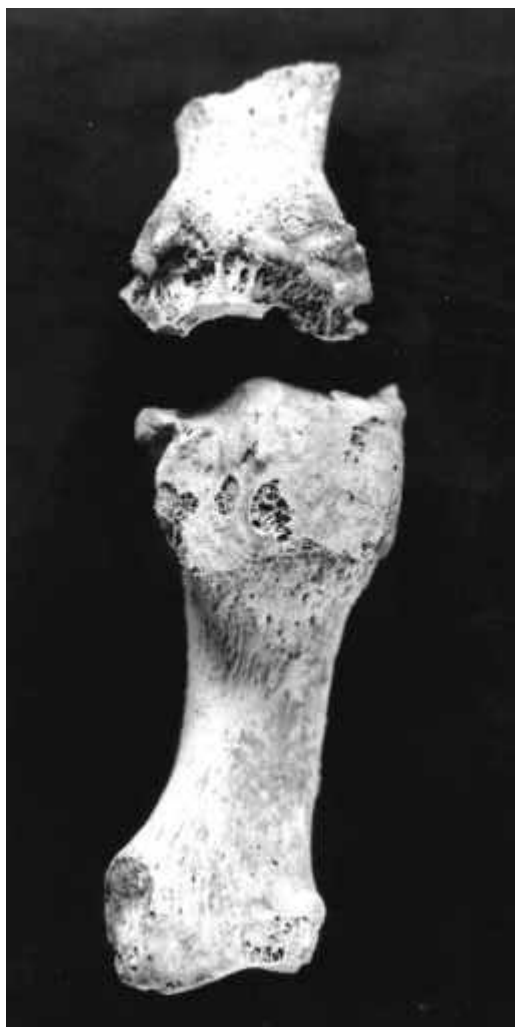
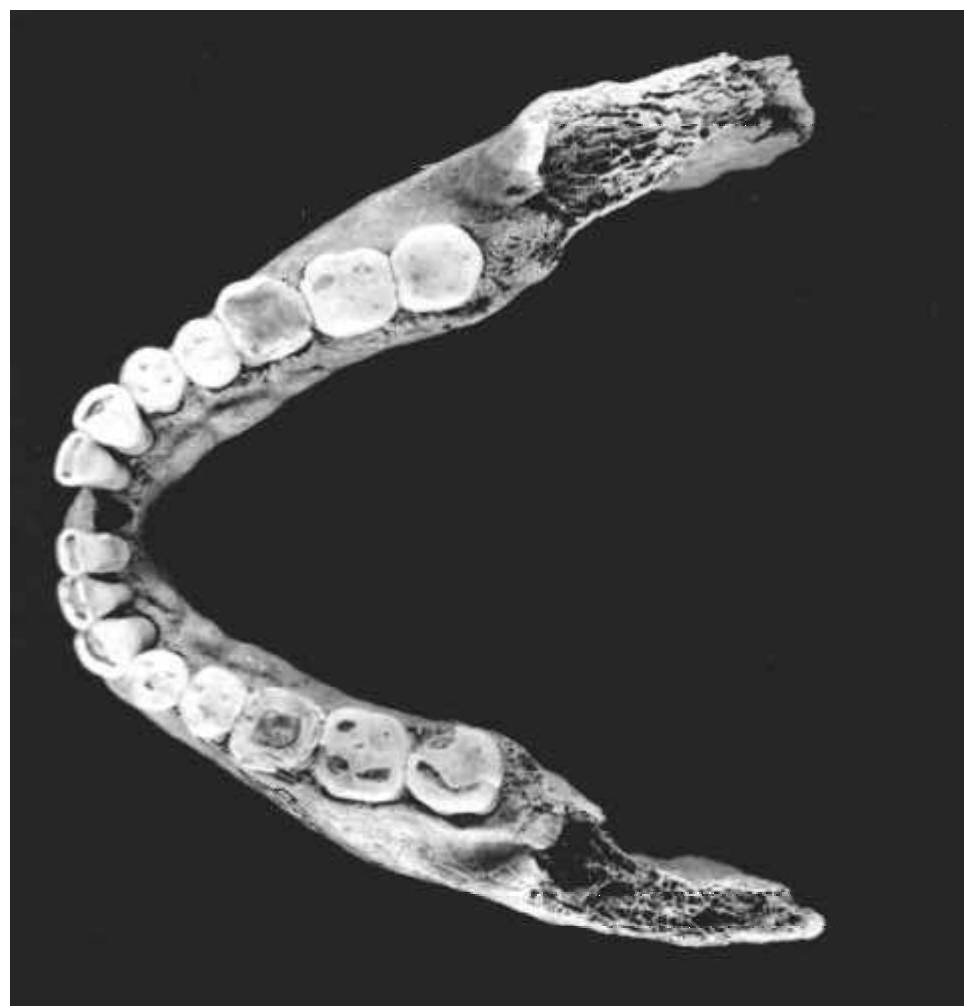
Plate 15 Context 1007:
[left] Metatarso
phalangeal joint of great
toe showing arthritis.

Plate 16 Context 1022:
[right] Mandible showing
torus formation lingually.



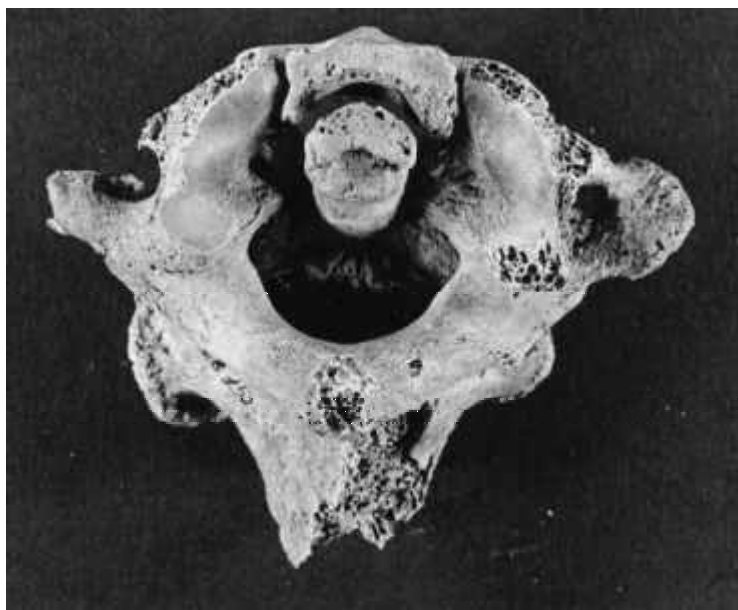


Plate 17 Context 1394: [left] Atlas and axis vertebrae. Gross arthritic change between odontoid process of axis and anterior arch of atlas.

Plate 18 Context 1701 [right].

Plate 19 Context 1822: [below] Malunited fracture of ulna.



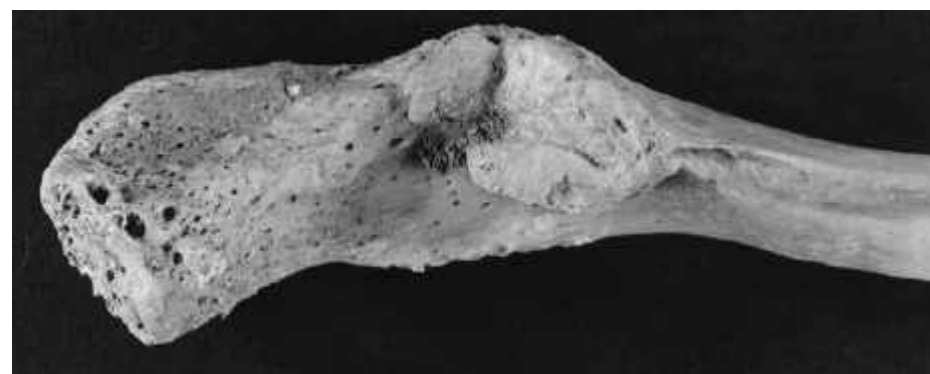
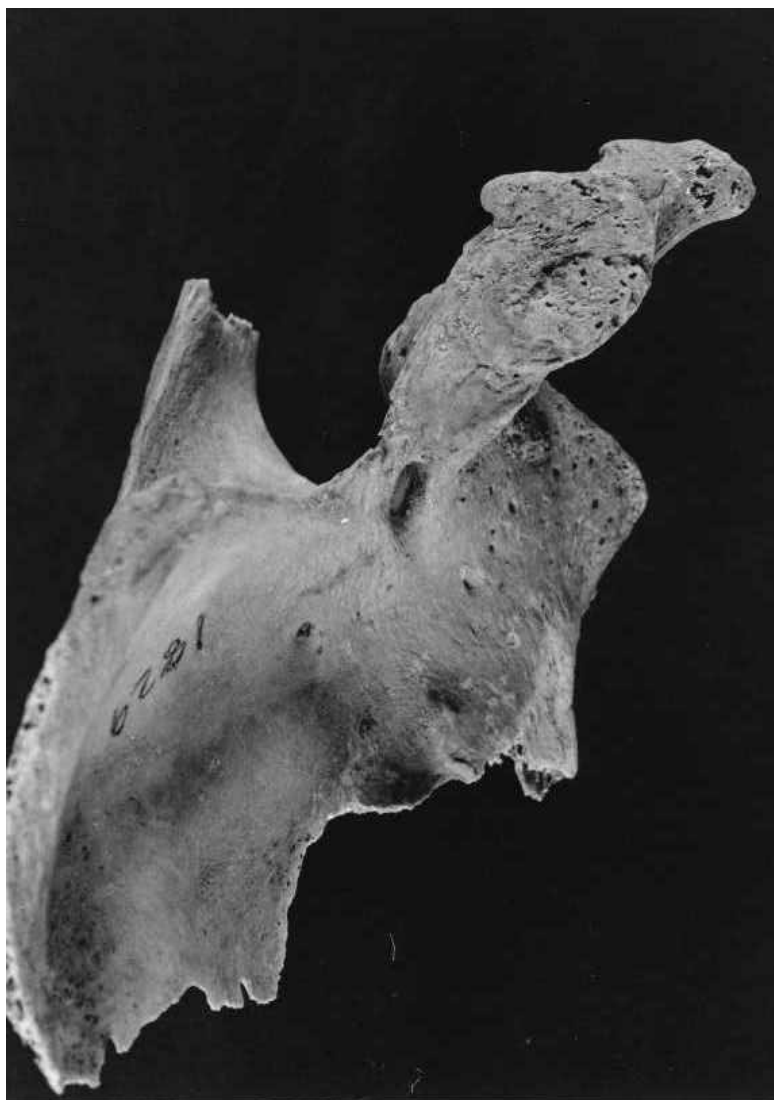

Plate 20 Context 1829 [left] Scapula (I) Acromion – unusual joint for clavicle – DISH; (ii) suprascapular foramen – congenital anomaly.

Plate 21 Context 1829 [above] Under surface of clavicle – a facet for articulation with acromion of scapula a ligament is attached here but DISH has caused unusual changes and development of a different type of joint.

Plate 22 Context 1833 [below] Arthritic cervical vertebrae.

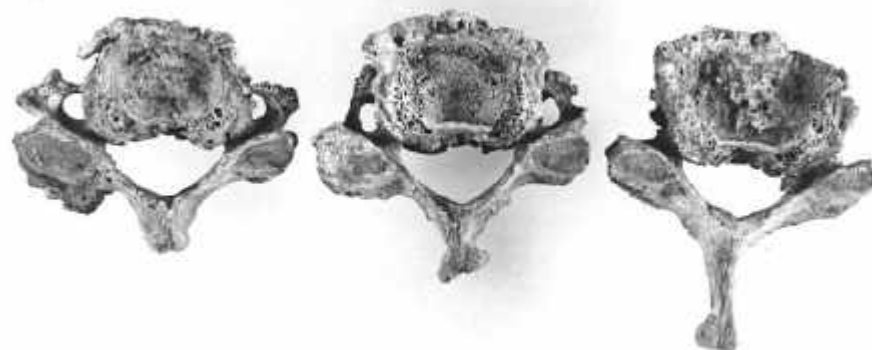
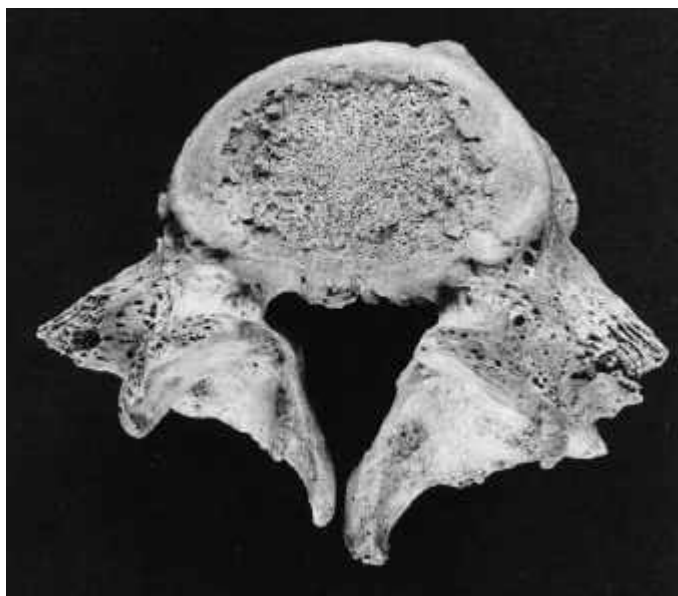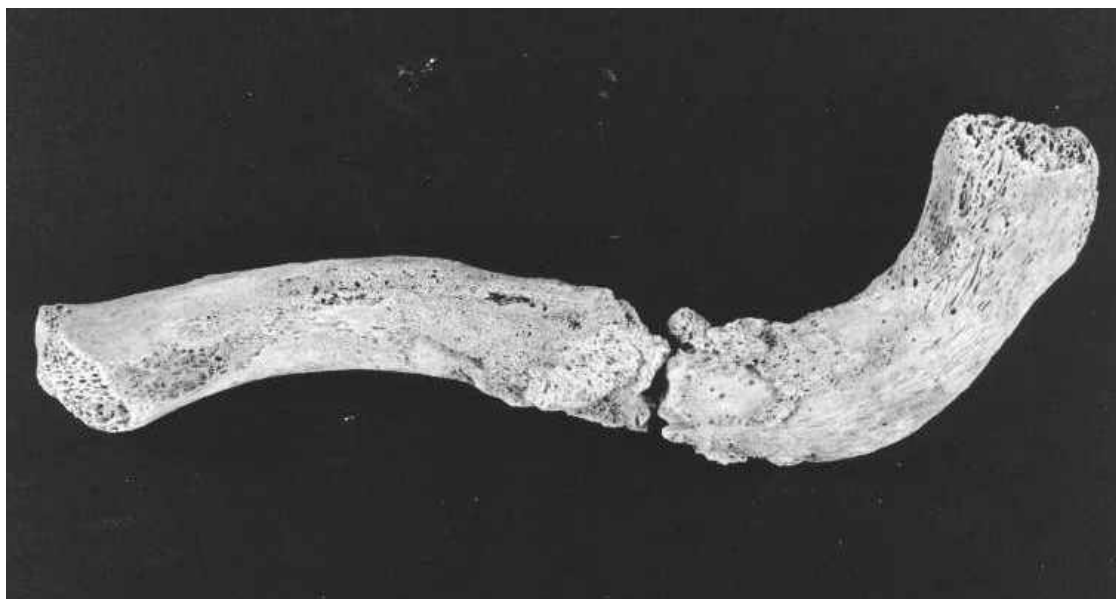


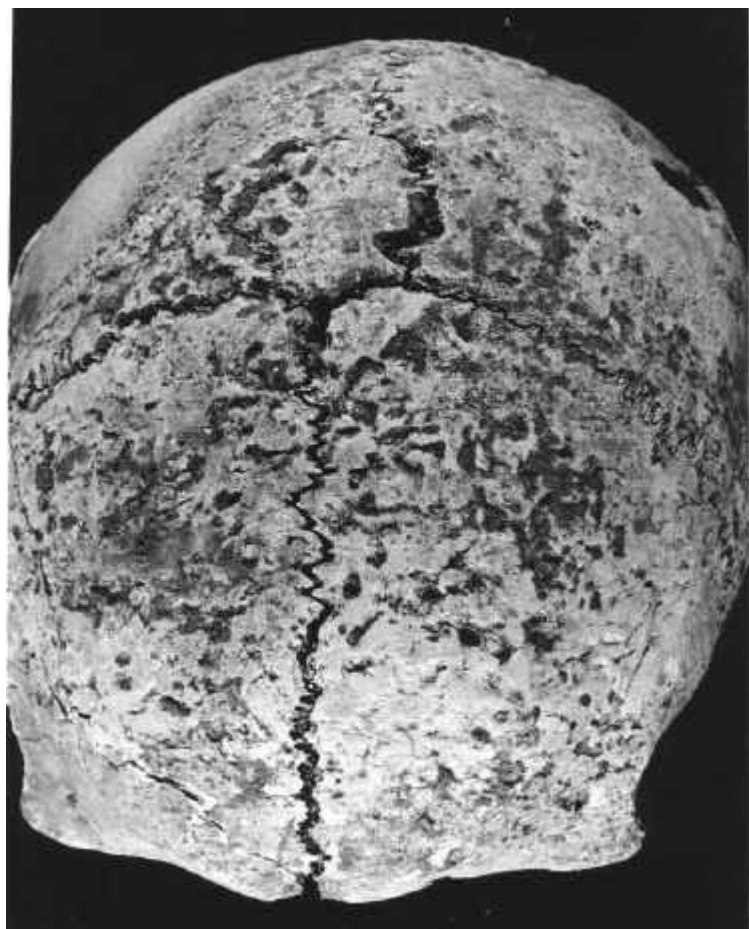

Plate 23 Context 1862 [left]: Unusual spinous process of L5 vertebra (bifid spinous process).

Plate 24 Context 1881 [below]: Fractured and healing left clavicle.

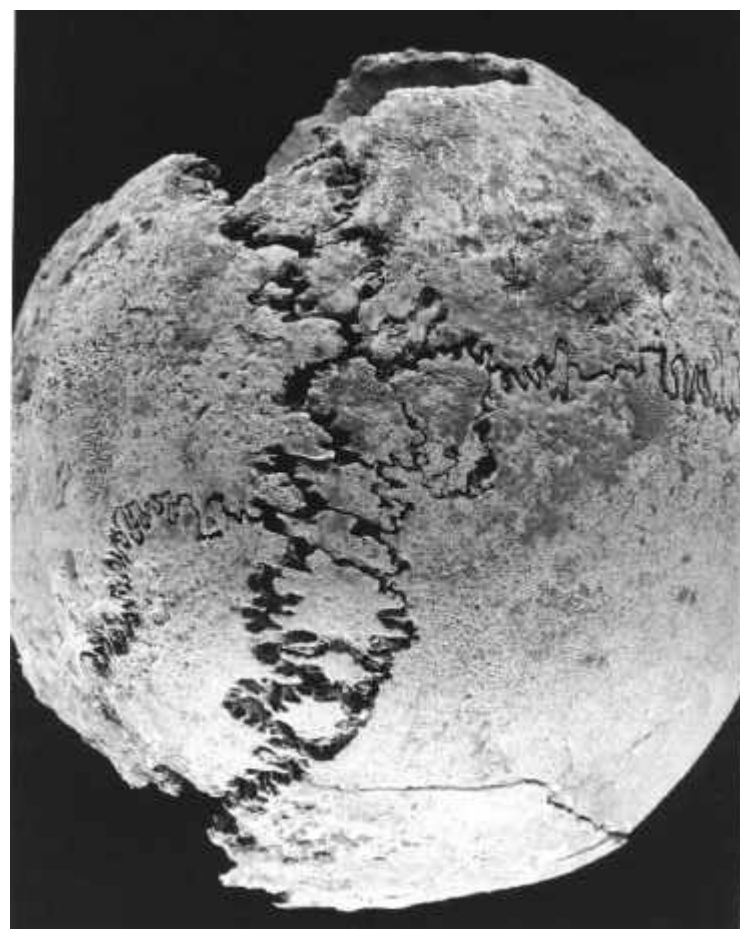


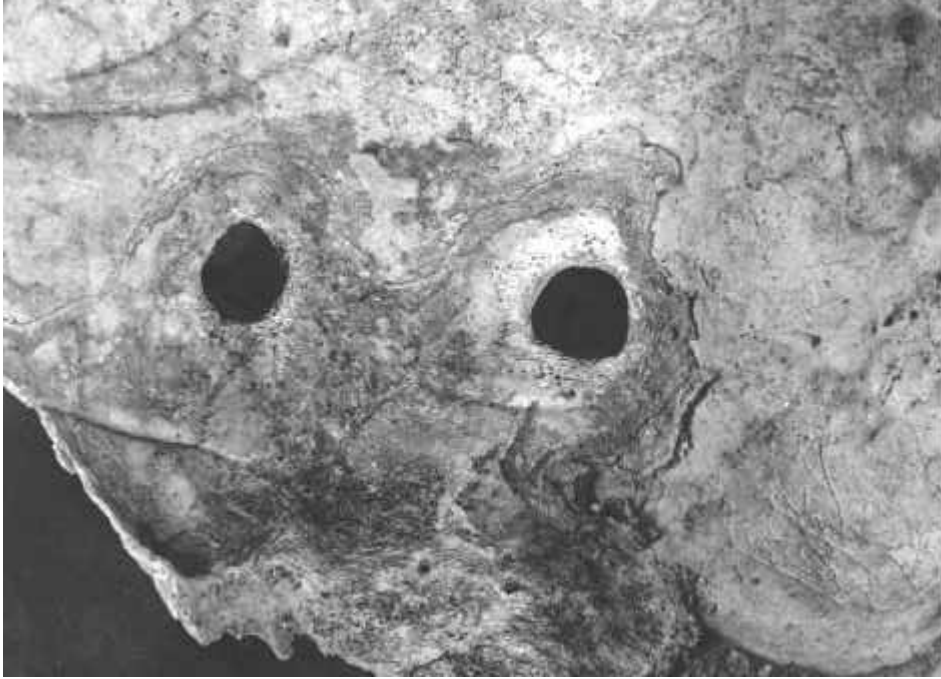


Plates 25 & 26

Context 1889:

Multiple Wormian bones, persistent metopic suture.





Plates 27 & 28 Context 1893: Trephine holes in right parietal bone of skull.

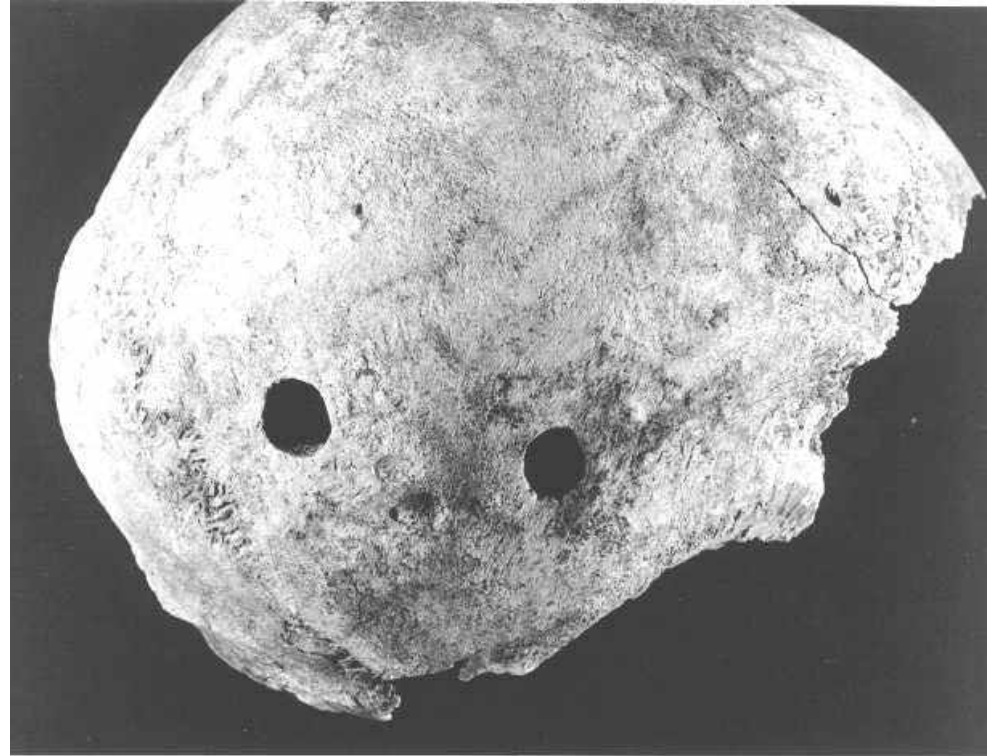
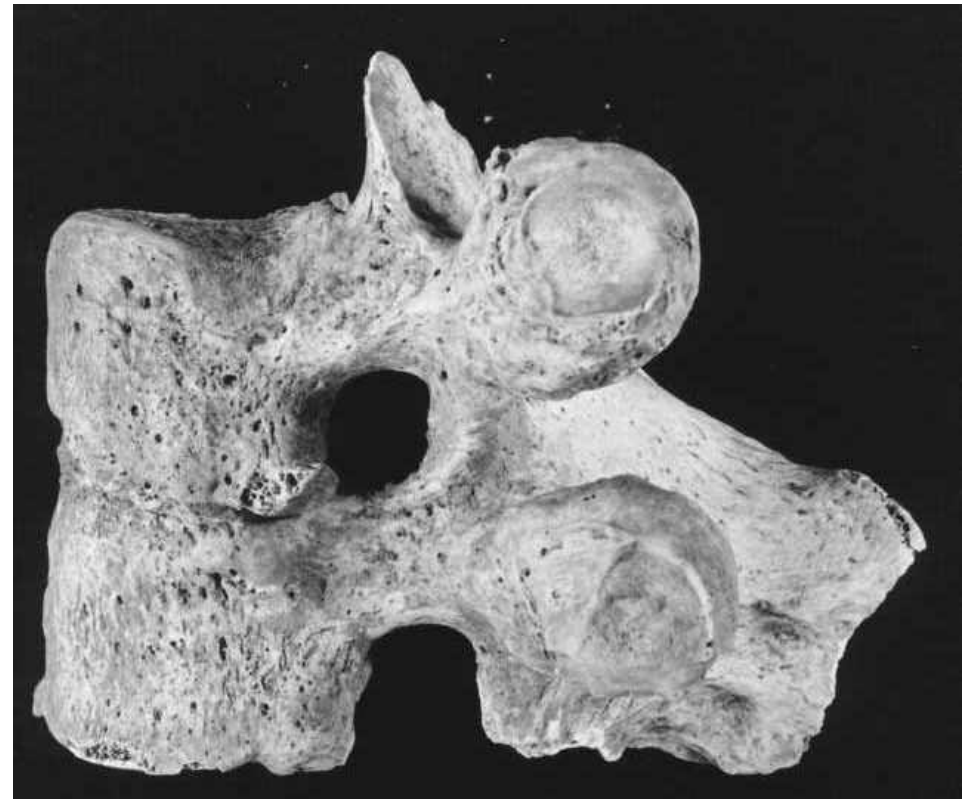



Plate 29 Context 1902 [left]: DISH-type lipping of the outer border of iliac crest anteriorly, also of the reflected head of rectus femoris.

Plate 30 Context 1916 [below]: Fusion of 2nd and 3rd thoracic vertebræ (congenital defect).



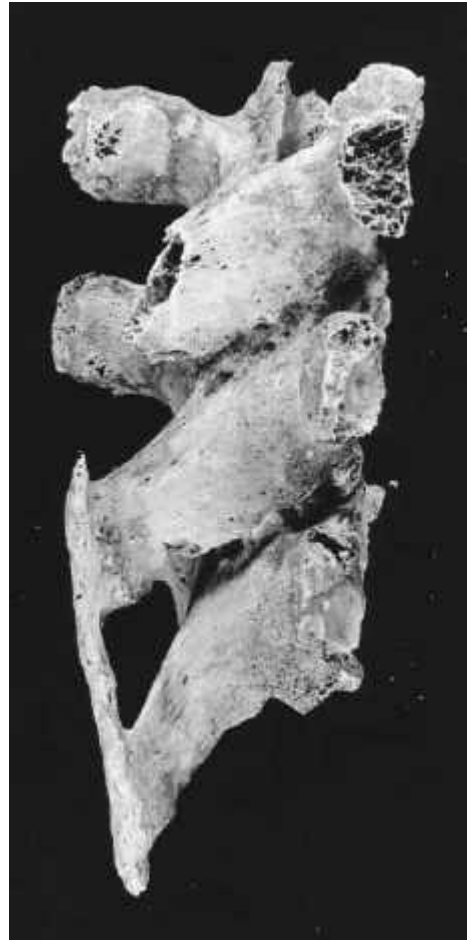

Plate 31 Context 2096 [far left]: Ridged public face.

Plate 32 Context 2179 [left] Fused supraspinous ligaments and pedicles but not interspinous ligaments.

Plate 33 Context 2185 [below left] : A bony over vertebral artery groove on right side of photo.

Plate 34 [below right] Congenitally fused premolar teeth.

